Radiance DIAGNOSTICS
experience health

Role of Diffusion Weighted Imaging in Prostate Cancer: Case reports.

Prostate cancer is the third leading cause of death and is the most common genitourinary malignancy in men. For the radiological evaluation of the prostate gland, magnetic resonance imaging (MRI) is a valuable imaging modality due to high tissue contrast, multiplanar imaging capabilities and the possibility of tissue characterization. In addition many new techniques in prostate gland MRI are under development and refinement. Recently, diffusion-weighted imaging (DWI) has emerged as a diagnostic technique in the evaluation of various abdominal lesions.

DWI reveals micro-molecular diffusion, which is the Brownian motion of the spins in biologic tissues. Restriction to the molecular diffusion of water in neoplastic tissues can be related both to the greater cellular density in the tissues, generated by the high index of neoplastic replication with a consequent reduction in the width of intercellular spaces, and to the ultrastructural alteration of the normal tissues. In prostate cancer, normal glandular architecture is disrupted, and is replaced by aggregated cancer cells and fibrotic stroma. These changes inhibit the movement of water molecules, with resultant restriction of diffusion and reduction of ADC values in the cancer tissue. The apparent diffusion coefficent (ADC) value has been reported to be useful for quantitatively distinguishing malignancy from benign lesions.

We hereby sought to present DWI features in prostate carcinomas which helped us to attain confident diagnosis of malignancy in renal failure patients wherein contrast scan was difficult. In our cases, the foci of the malignancy in the prostate gland were readily detected on DWI.

The reported ADC values of the normal peripheral (1.60–1.97x10^{-3} mm^2/s), transitional zones (1.27–1.79 x$10^{-3}$$mm^2/s$), and cancers (0.90–1.38 x$10^{-3}$$mm^2/s$)of the prostate gland vary. This is attributed to many reasons like the b value, strength of the magnetic field etc.

Case 1:

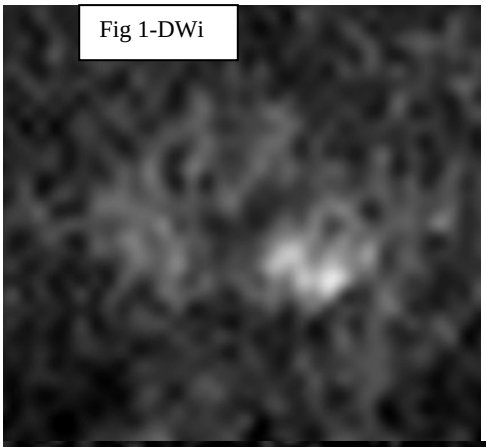

Fig 1-DWi

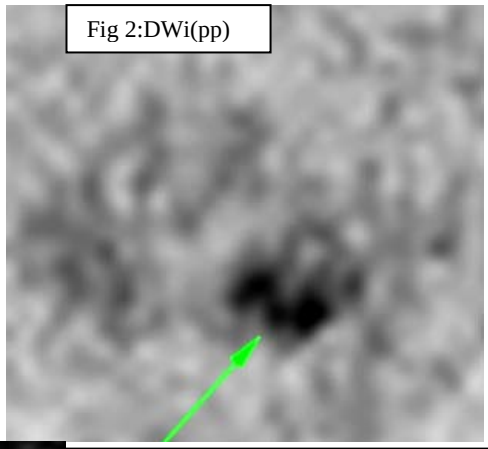

Fig 2:DWi(pp)

Fig 1 & 2: Hyperintense foci suggestive of restricted diffusion is seen in the peripheral zone on the left side.

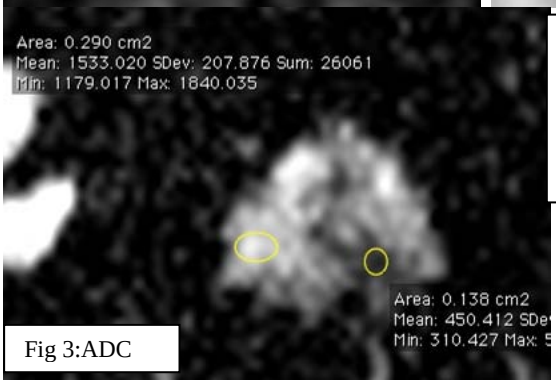

Fig 3:ADC

Fig 3: Low ADC values are seen in the peripheral zone on the left side affected by neoplasm. The ADC value is $0.45x10^{-3}mm^2/s$ .The normal peripheral zone on the right side shows ADC value of $1.53x10^{-3}$ mm^2/s.

Case 2:

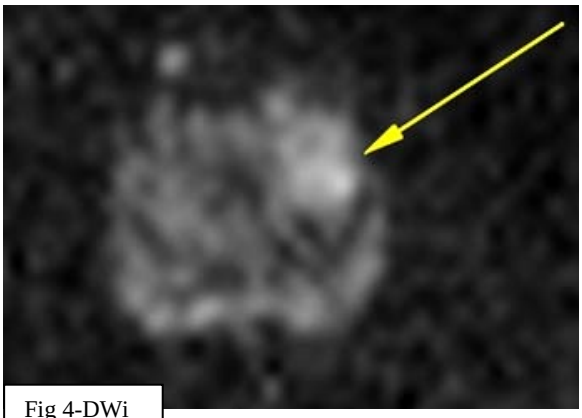

Fig 4-DWi

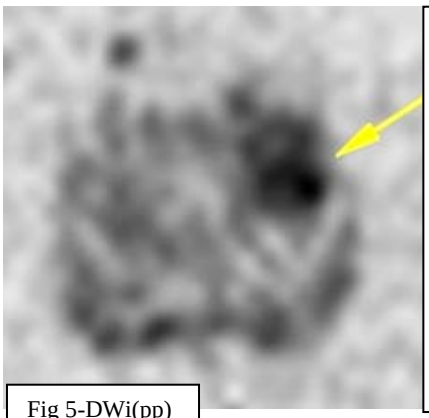

Fig 5-DWi(pp)

Fig 4 & 5: DWi sequences show hyperintense foci suggestive of restricted diffusion is in the anterior aspect of peripheral zone on the left side

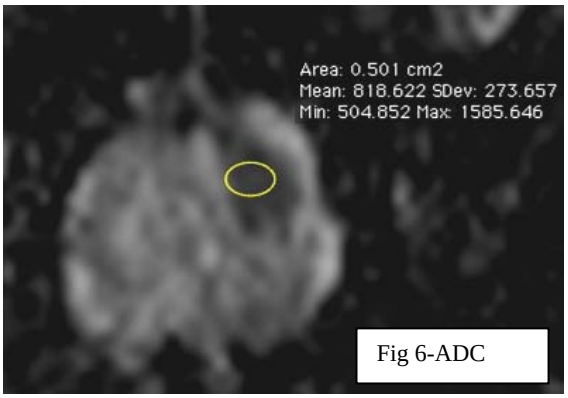

Fig 6: ADC mapping shows low ADC values in the anterior part of peripheral zone on the left side affected by the neoplasm.ADC values corresponds to 0.81 $x10^{-3}$ mm^2/s which is highly suggestive of cancer cells.

A study by Ren et al. reported that DWI was able to discriminate normal prostate gland, benign prostatic hyperplasia (BPH) nodules, cysts and carcinomas. In this study, the ADC values of BPH nodules were between those of normal parenchyma and those of cancers.
DWI has advantages such as short acquisition time and high contrast resolution between tumors and normal tissue. However, this technique is limited by poor spatial resolution and the potential risk of image distortion caused by post-biopsy hemorrhage, which accentuates the need for dynamic contrast enhanced scans, spectroscopy and other routine imaging techniques.

In conclusion, DWI provides excellent images of malignant lesions of the prostate, against suppressed background signal. Pre biopsy MRI helps localise the malignant nodule thereby increasing the sensitivity for cancer diagnosis.
DWi has potential to increase the specificity of prostate cancer detection because ADC are significantly lower in malignant compared with non malignant prostate tissue.

Regards,

Dr.Deepa S.Nadkarni / Dr.Shaikh M.Mazhar

N.B: These cases are authentic and from the archives of Radiance Diagnostics. For any queries / suggestions/feedback write to us at radiance@radiancediagnostics.in