Intramedullary Osteoid Osteoma: A case report

Clinical history: A 17 year old boy presented with history of pain in the lower end of femur and knee since past 2 months, aggravated in the past few weeks. The pain was more noticeable at night.There was no history of antecedent trauma.

MR/CT imaging findings: On plain CT scan, lytic lesion with sclerotic rim is noted in the medullary cavity of meta-diaphyseal region of distal end of femur. It measures 1.3 x 1.0cm in size.

On MR T1W and T2W images, the lesion shows ill defined margins and low signal intensity. Dynamic post contrast MRI study shows intense enhancement in the central part of the lesion representing a vascular nidus. The enhancement is seen on early post contrast phases and is seen to persist on delayed images obtained subsequently. Area surrounding the lesion actually represents marrow edema as evident on CT as ground glass density and hyperintensity on T2Wi.The edema is seen to cross the physeal plate with extension into the epiphysis. Patchy inhomogeneous enhancement is noted in the entire area on delayed post contrast MR study.

No cortical break or endosteal scalloping is seen.
Thick periosteal reaction is noted in distal shaft of femur, measuring 0.4 cm in maximum thickness. Edema is seen in soft tissues adjacent to the periosteal reaction.
No obvious associated soft tissue component is seen in extra-osseous or intra-osseous region.

Diagnosis: Intramedullary osteoid osteoma.

Discussion: Osteoid osteoma is a common benign bone lesion in the pediatric and young adult populations. Males are more commonly affected. Long bones are the most common location for these lesions with the majority occurring in the lower extremity.Presenting symptoms in children are often pain, which is worse at night and relieved with salicylates, and a noticeable limp.

The location of these lesions within the bone may vary. The classic and most common location is within the cortex. These lesions have also been found in the periosteal region of long bones. Children can have lesions involving the epiphyses of long bones. In all patients, the intramedullary location within bone is relatively infrequent, 2 in 38 in one study and 6 in 67 in another. It's the intramedullary location which makes the imaging appearance and subsequent diagnoses a challenging task. This is mostly due to extensive perilesional marrow edema.

Typical radiographic findings are of a dense ivory-like sclerotic mass attached to the bone with sharply demarcated borders. CT scans generally show a small lucent nidus surrounded by reactive sclerosing bone, sometimes seen on plain films. Visualizing the nidus by routine MRI and sometimes by CT scan can be difficult; however the Dynamic gadolinium-enhanced MR imaging techniques demonstrates the osteoid osteomas with greater conspicuity. Possible explanations for this difference include the presence of associated marrow edema, periosteal edema or new bone formation, marrow sclerosis, cortical thickening, or calcification of the nidus obscuring the lesion to varying degrees. These findings can obscure the margins of the lesion and make it appear larger and more aggressive.

The differential diagnosis of an osteoid osteoma includes osteoblastoma, osteomyelitis, eosinophilic granuloma, osteogenic sarcoma, Ewing's sarcoma or healing fracture.Treatment options for an osteoid osteoma include prolonged non-steroidal anti-inflammatory drug (NSAID) use, CT-guided RF ablation and surgical excision.

Osteoid osteoma should be kept in mind as a source of pain in the younger age group, with or without "classic" radiographic features.

CONCLUSION:

- **Osteoid osteomas can be imaged with greater conspicuity by using Dynamic gadolinium-enhanced instead of nonenhanced MR imaging and with conspicuity equal to or better than that obtained with thin-section HRCT.**
- **Dynamic gadolinium-enhanced MR imaging may also be diagnostic in cases in which CT images show findings suspicious of an osteoid osteoma.**
- **Considering the rare intramedullary location of osteoid osteoma in our case, the Dynamic gadolinium-enhanced MRI has helped us to attain the diagnosis of osteoid osteoma over that of a more aggressive neoplasm or infection.**

Fig 1:T1Wi and Fig 2: PDFS MRI Sag: Ill defined low signal intensity lesion in the intramedullary part of distal femur. Surrounding marrow edema mimics aggressive lesion.

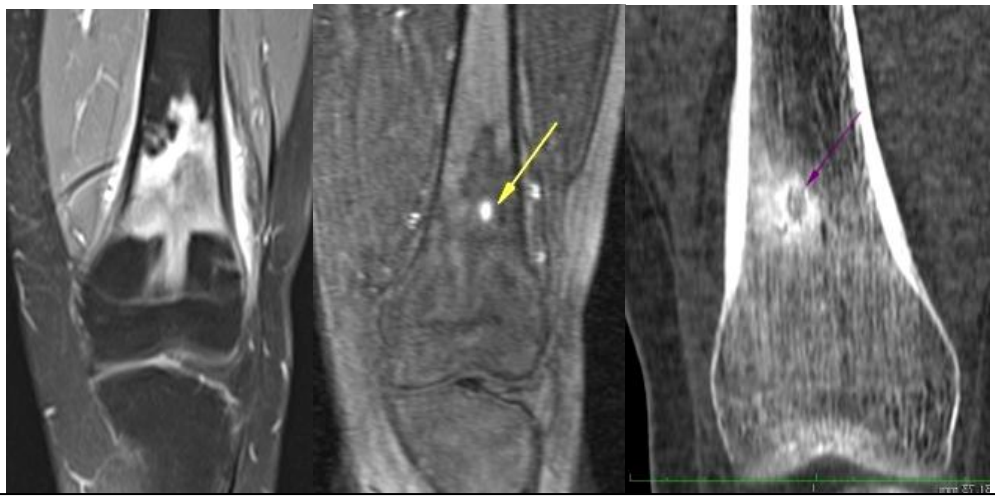

Fig 3: Delayed post contrast coronal shows enhancement in the entire involved area.
Fig4: Dynamic contrast MR coronal shows intensely enhancing central part (yellow arrow) in the early phase representing vascular nidus.(Heroic study in this case).
Fig 5: CT coronal: Lytic lesion (pink arrow) with sclerotic rims in the distal shaft of femur. Note the adjacent periosteal reaction along the shaft.

Dr.Deepa S.Nadkarni / Dr.Shaikh M.Mazhar