

SINUS TARSI SYNDROME – A Case Report

A clinical disorder characterized by pain and tenderness on the lateral side of the hindfoot at the sinus tarsi in between ankle and heel. It is often associated with ankle sprains and most commonly presents in young males of 30 to 40 years of ages.

Sinus tarsi syndrome can be primarily described as instability of the subtalar joint due to ligamentous injuries that result in synovitis and scar tissue formation in the sinus tarsi. Haemorrhage or inflammation of the synovial recesses of the sinus tarsi can also cause scarring without tears of the associated ligaments.

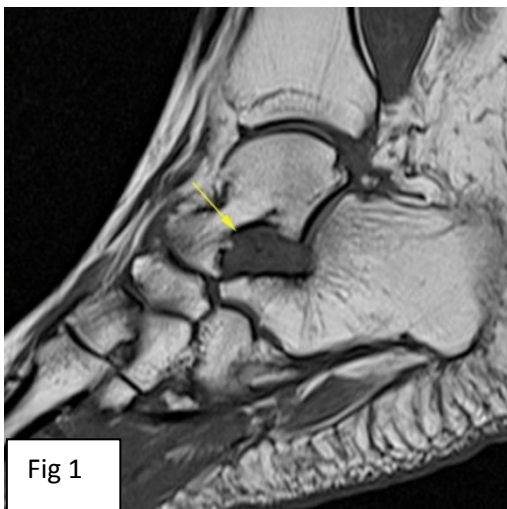


Fig 1

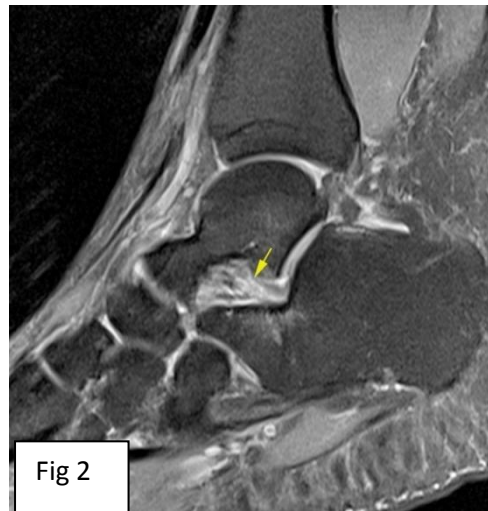


Fig 2

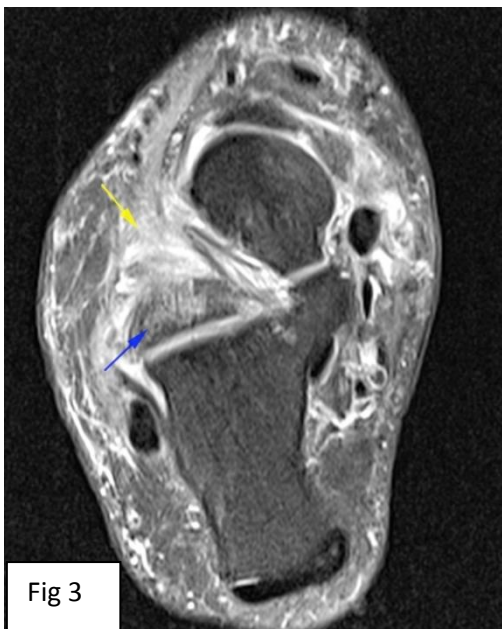


Fig 3

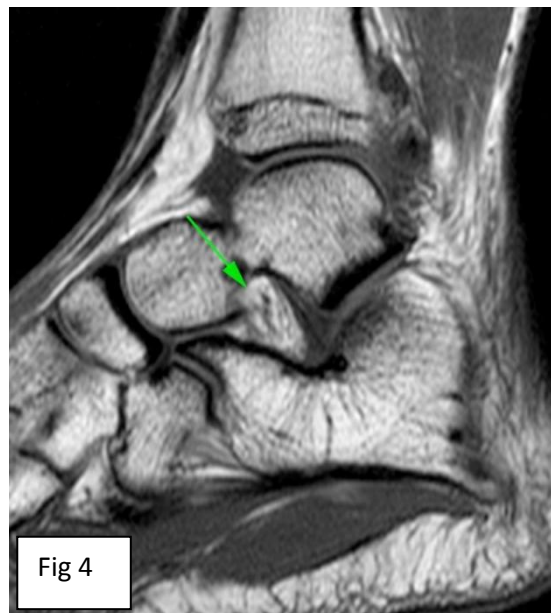

Fig 4

MRI findings: Obliteration of fat in sinus tarsi which is replaced by soft tissue (inflammatory tissue , yellow arrows) appearing hypointense on T1WI (Fig 1) and hyperintense on PDFS sequences(Fig 2 & 3). The ligaments however appear intact. Mild edema is noted in subchondral region of talus and calcaneum around the sinus tarsi (Fig 3, blue arrow).

Note the bright T1W fat signal in sinus tarsi in normal subject (Fig 4-green arrow).

Regards, **Dr.Deepa S. Nadkarni / Dr.Shaikh M.Mazhar**

N.B: This case is authentic and from archives of **Radiance Diagnostics**. For any queries//feedback write to us at radiance@radiancediagnostics.in Case of the month can also be accessed anytime online at **VIEW BOX** at www.radiancediagnostics.in